


History Examination Diagnosis Treatment Finish

Question | One best answer

How will you relieve Mr. Hashim's pain?

- Oral tramadol 50 mg
- Intramuscular tramadol 50 mg
- Intravenous tramadol 50 mg
- Intravenous diclofenac 100 mg

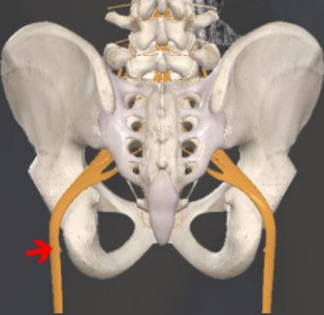


Submit

History Examination Diagnosis Treatment Finish

Question | Type in answer


Please name this structure



Type answer here Submit

History Examination Diagnosis Treatment Finish

Question | One best answer



How do you examine this structure?

- Ask the patient to move the big toe up
- Ask to patient to move his hip
- Ask the patient to move the ankle down
- Ask the patient to bend the knee joint

Submit

History

Examination

Diagnosis

Treatment

Finish

Question | One or more than one response

Choose differential diagnoses for Mr Hashim

- Dislocation of the hip
- Fracture neck of the femur
- Fracture acetabulum
- Fracture intertrochanter
- Fracture shaft of the femur

Submit

History

Examination

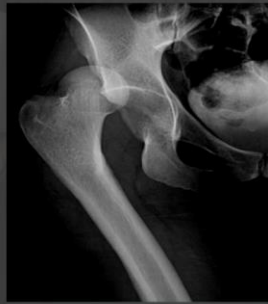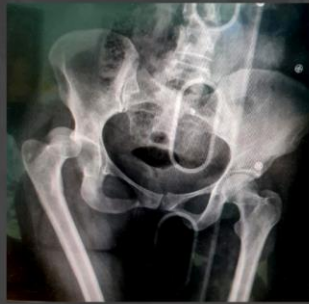Diagnosis

Treatment

Finish

Question | Type in answer

What is the final diagnosis?



Type answer here

of the right hip joint

Submit

History

Examination

Diagnosis

Treatment

Finish

Question | One or more than one response

Why it's a posterior dislocation?

- Leg is short
- Adducted
- Internally rotated
- Flexed
- External rotation
- Abduction

Submit

History

Examination

Diagnosis

Treatment

Finish

Question | Multiple choice

Which statement regarding management of hip dislocation is correct?

- It is an emergency and must be reduced in less than 6 hours of injury
- It is not an emergency and can be treated electively

Submit

History

Examination

Diagnosis

Treatment

Finish

Question | One or more than one response

What are the important steps after closed reduction?

- Check the stability clinically
- Check the sciatic nerve
- Radiograph of the hip
- CT scan of the hip
- MRI of hip

Submit

History

Examination

Diagnosis

Treatment

Finish

Question | One or more than one response

Why CT scan is mandatory after closed reduction of the dislocated hip?

- To assess congruent reduction
- Exclude fracture femoral head or acetabulum
- Presence of loose fragment pieces inside the joint
- Evaluation of sciatic nerve injury

Submit

History

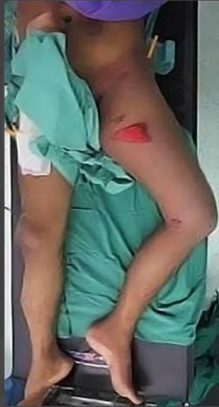Examination

Diagnosis

Treatment

Finish

Question | Type in answer



What type of hip dislocation is shown in the photograph?

Type answer here

Submit

History

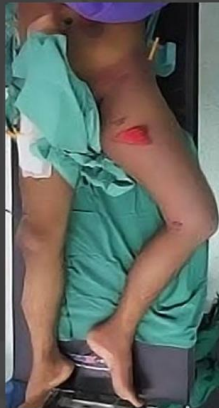Examination

Diagnosis

Treatment

Finish

Question | One or more than one response



Why is it anterior dislocation?

- Leg is short
- Abducted
- Externally rotated
- Flexed
- Internally rotated

Submit